

Outbreaks of jaundice in young calves – a novel disease?

M. Metzner¹, M. Wieland¹,
M.C. Langenmayer³, B.K. Weber², A. Hafner-Marx²,
W. Klee¹

¹ Clinic for Ruminants with Ambulatory and Herd Health Services, LMU Munich

² Bavarian Health and Food Safety Authority, Oberschleissheim

³ Institute of Veterinary Pathology, LMU Munich

European Buiatrics Forum, Nov. 16th – 18th, 2011, Marseille

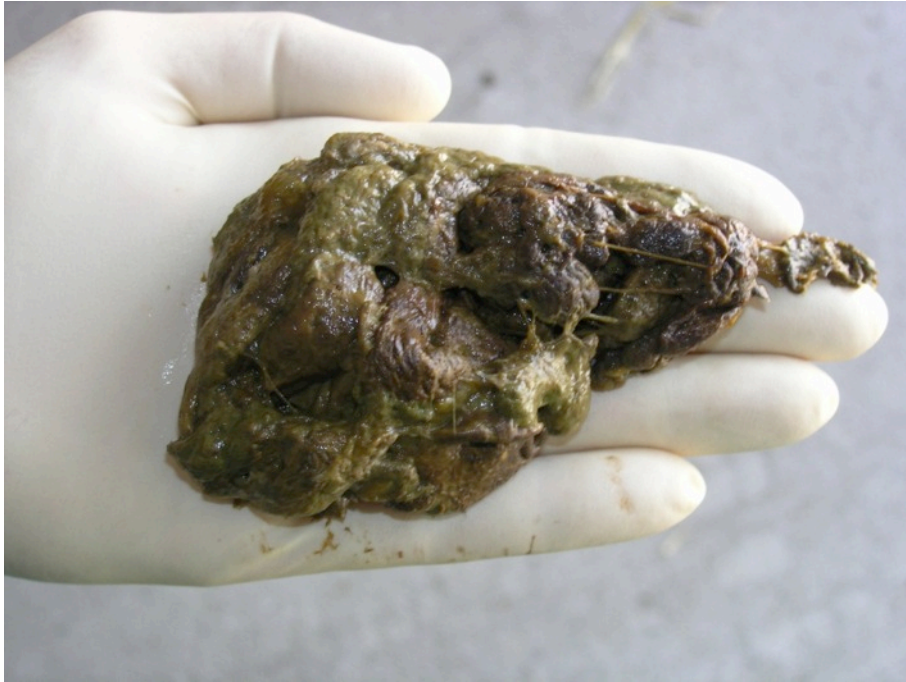Introduction

- Primary hepatopathy in young calves is very rare, at least in our clinic
- First report from a practitioner in Sep., 2010
- First case in our clinic in Nov., 2010
- Since then 56 confirmed cases on 36 farms

Past medical history

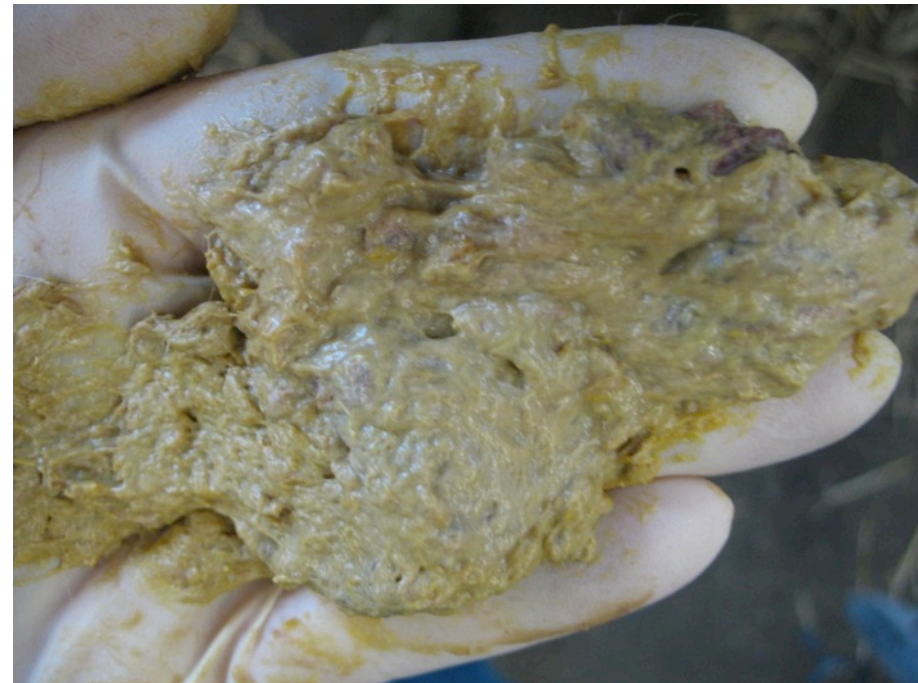- Age at onset of the disease: 7 to 10 days
- In most cases diarrhea occurred before the animals fell ill, but at this stage the feces were normal

Characteristic aspect of the feces



Brownish-reddish

Color of loam,
consistency of putty



General condition



Listlessness



Recumbency

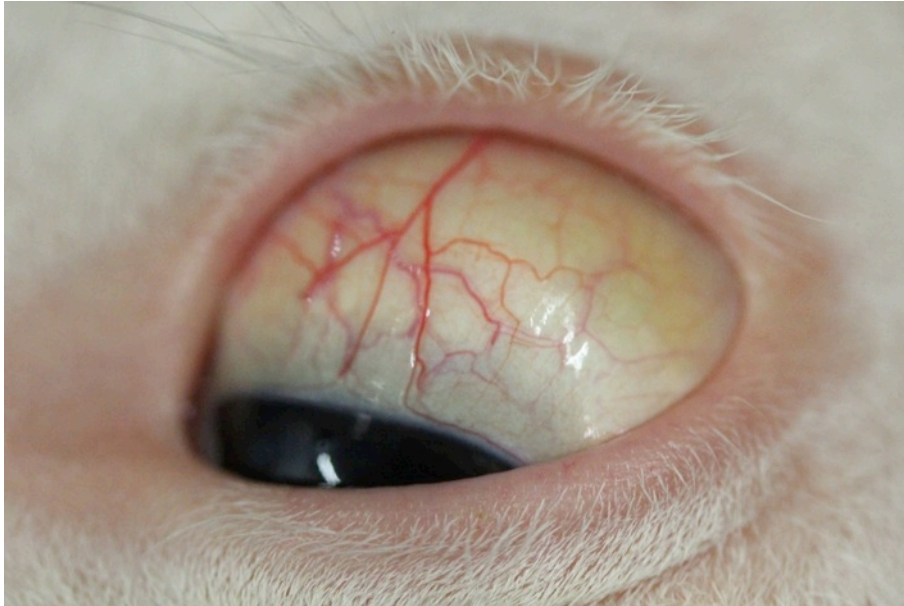

**Convulsions and seizures,
Loud screaming just before
death**

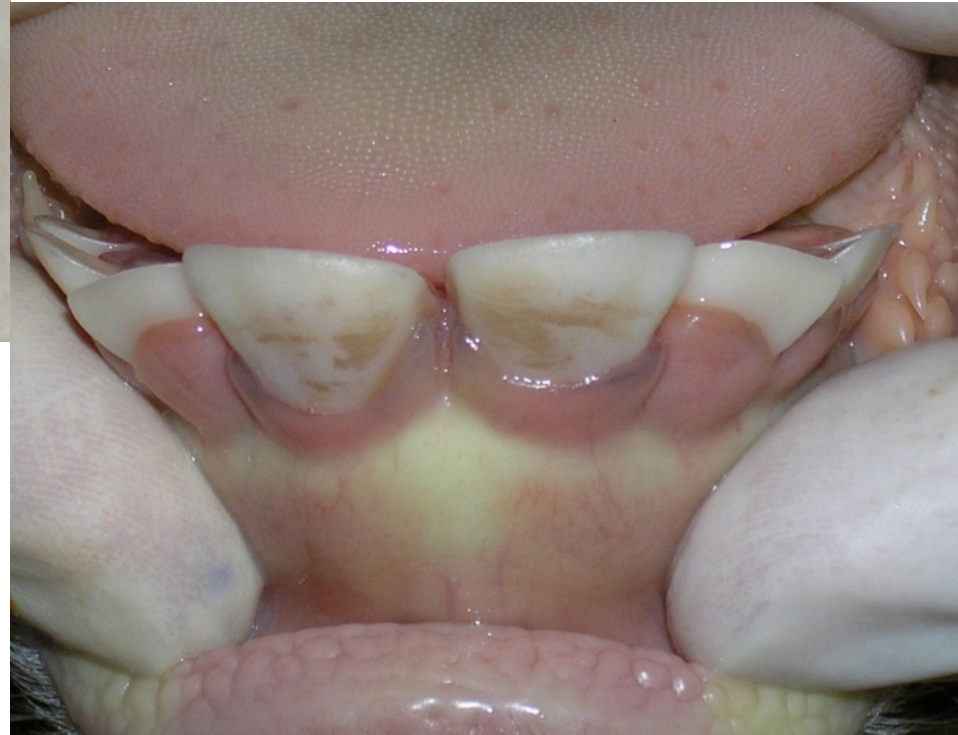Ikterus



Klinik für Wiederkäuer
mit Ambulanz und Bestandsbetreuung



**Yellowish discoloration of the sclera
(Total bilirubin: 134 $\mu\text{mol/l}$)**



**Gingiva around the incisors
may become dark-grey
(few cases only)**

Laboratory findings



Klinik für Wiederkäuer
mit Ambulanz und Bestandsbetreuung

Parameter	Minimum	Maximum	Reference values
Total bilirubin [$\mu\text{mol/l}$]	-	315	≤ 8.5
Dir. bilirubin [$\mu\text{mol/l}$]	-	75	≤ 3.4
GLDH [U/l]	-	2213	≤ 16
L-Lactate [mmol/l]	-	22.4	≤ 2.2
Hematocrit [%]	24	59	30 – 36
Total protein [g/l]	22.9	72.7	55 – 70
Albumin [g/l]	15.5	33.7	30 – 40
Glucose [mmol/l]	0.0	8.8	3.9 – 6.6

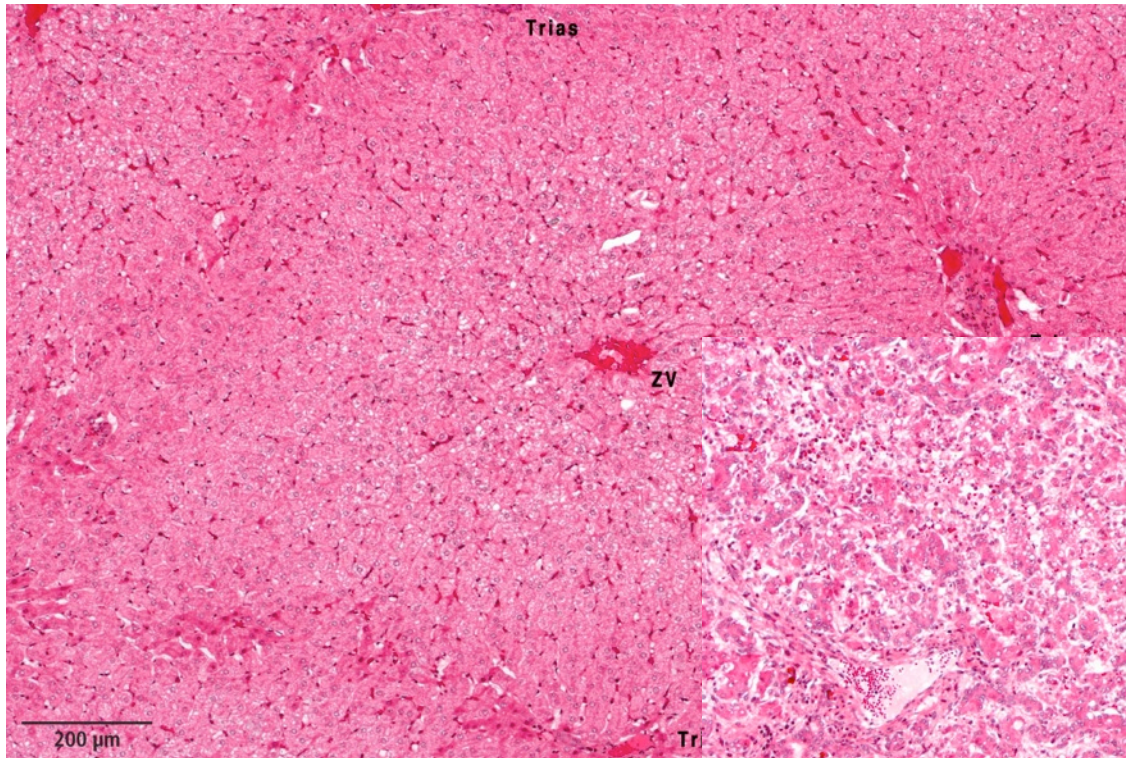
Post-mortem findings

- Severe hepatopathy
- Massive disruption of liver architecture
- Necrosis of hepatocytes
- Extensive bile duct proliferation
- Mild inflammation
- Fibrosis and intrahepatic cholestasis
- No specific alterations in other organs

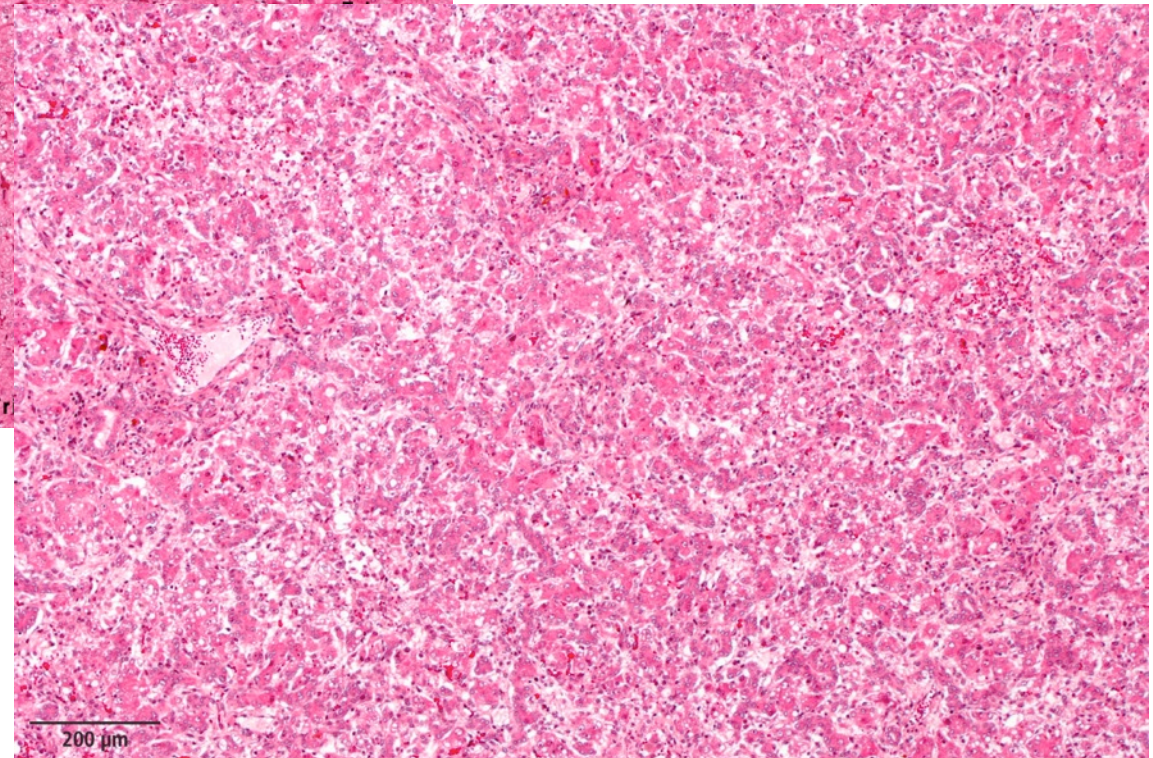
Liver histology



LMU München
Klinik für Wiederkäuer
mit Ambulanz und Bestandsbetreuung



Physiological
liver architecture



Liver of an affected calf

54 rule outs (Consultant, Cornell University)

Intoxications:

Oak, algae, mercurialis, phosphor, copper, iron, zinc, pyrrolizidine alkaloid, aflatoxin, bee sting, wasp sting, brassica sp., gossypol, fern, onion, hepatogenous photosensitization, locoweed, solanum, tremetol, Terminalia oblongata

Bacterial infections:

Salmonellosis, anthrax, *C. haemolyticum*, *C. novyi*, clostridial myositis, leptospirosis, melioidosis

Viral infections:

Leukosis, Rift Valley fever, Wesselsbron disease

Parasitic diseases:

Anaplasmosis, babesiosis, fasciolosis, sarcocystosis, sawfly larval toxicity, theileriosis, trypanosomiasis

Others:

Bile duct atresia, bladder neoplasia, cholelithiasis, extrahepatic bile duct obstruction, ruptured gallbladder, bile duct neoplasia, congenital hepatic fibrosis, blood transfusion reaction, hemolytic anemia, immune idiopathic hemolytic anemia, hepatic fatty cirrhosis, ketosis, liver abscess, postparturient hemoglobinuria, shock, snakebites

54 rule outs (Consultant, Cornell University)



Klinik für Wiederkäuer
mit Ambulanz und Bestandsbetreuung

Intoxications:

~~oak, algae, mercurialis, phosphor, copper, iron,
zinc, pyrrolizidine alkaloid, aflatoxin, bee sting, wasp sting, brassica sp., gossypol,
fern, onion, hepatogenous photosensitization, locoweed, solanum, tremetol,
Terminalia oblongata~~

Bacterial infections:

~~Salmonellosis, anthrax, C. haemolyticum, C. novyi, clostridial myositis,
leptospirosis, melioidosis~~

Viral infections:

~~leukosis, rift valley fever, wesselsbron disease~~

Parasitic diseases:

~~anaplasmosis, babesiosis, fasciolosis, sarcocystosis, sawfly larval toxicity,
theileriosis, trypanosomiasis~~

Others:

~~bile duct atresia, bladder neoplasia, cholelithiasis, extrahepatic bile duct
obstruction, ruptured gallbladder, bile duct neoplasia, congenital hepatic fibrosis,
blood transfusion reaction, hemolytic anemia, immune idiopathic hemolytic
anemia, hepatic fatty cirrhosis, ketosis, liver abscess, postparturient
hemoglobinuria, shock, snakebites~~

Further investigations

Agent	Sample	Result
Salmonella	carcass	neg.
Leptospira	liver	neg.
BVD virus	blood/organs	neg.
Copper, zinc, iron	blood/liver	neg.
Aflatoxin	liver	neg.
Deoxynivalenol	liver	neg.
Ochratoxin A	liver	neg.
Zearalenon	liver	neg.
Toxicological screening (Gaschromatographie / Massenspektrometrie)	liver	neg.

Case definition

- Calves 1 – 3 weeks old and
- High total bilirubin ($> 20 \mu\text{mol/l}$) and/or
- High GLDH ($> 50 \text{ U/l}$) and/or
- Pathological findings in the liver: dystrophy

Origin of the cases

(10/11/2011)



Klinik für Wiederkäuer
mit Ambulanz und Bestandsbetreuung

Origin	Number of farms	Number of calves	# of cases with post mortem
Clinic for Ruminants	13	21	12
Post mortem only*	13	25	25
Local veterinarians	10	10	6
Total	36	56	43

Number of cases per farm confirmed by inclusion criteria: 1 – 4

Number of cases per farm as described by the farmers: 1 – 10

* Bavarian Health and Food Safety Authority
(direct transfer by local veterinarians)

Results of a survey on affected farms

- First cases in Sept., 2010
- Some farms reported high rates of disease and mortality
- All calves received colostrum or milk (only one farm: milk replacer)
- In 32 out of 35 farms calves received one particular commercial product for prevention and treatment of calf diarrhea (VitaKur, Fa. Josera)
- Cases that didn't receive that product:
 - farm 1: only 1 case, clinical finding: sodium chloride intoxication
 - farm 2: only 1 case, farmer used the product, but affirmed that he didn't administer it to the concerned calf
 - farm 3: only 1 case, inclusion by post-mortem finding

Examination of two batches of the concerned product

Batches belonged to farms on which they had been administered to affected calves

- Copper: normal
- Aflatoxin: neg.
- Toxicological screening:
 - Vanillin
 - Methylsalicylate (traces, only one batch)
- Bacteriological screening: neg.
- Pyrrolizidin alkaloids: neg.
- Ricins: neg.

Feeding trial

(approved by Regierung von Oberbayern: 55.2-1-54-2532-37-11)



Klinik für Wiederkäuer
mit Ambulanz und Bestandsbetreuung

Inclusion criteria:

- 8 calves
- Age at enrollment: 1 day
- Clinical examination: healthy
- Blood-serological examination: no abnormal findings
- Fed only with colostrum
- No previous therapy

Feeding trial

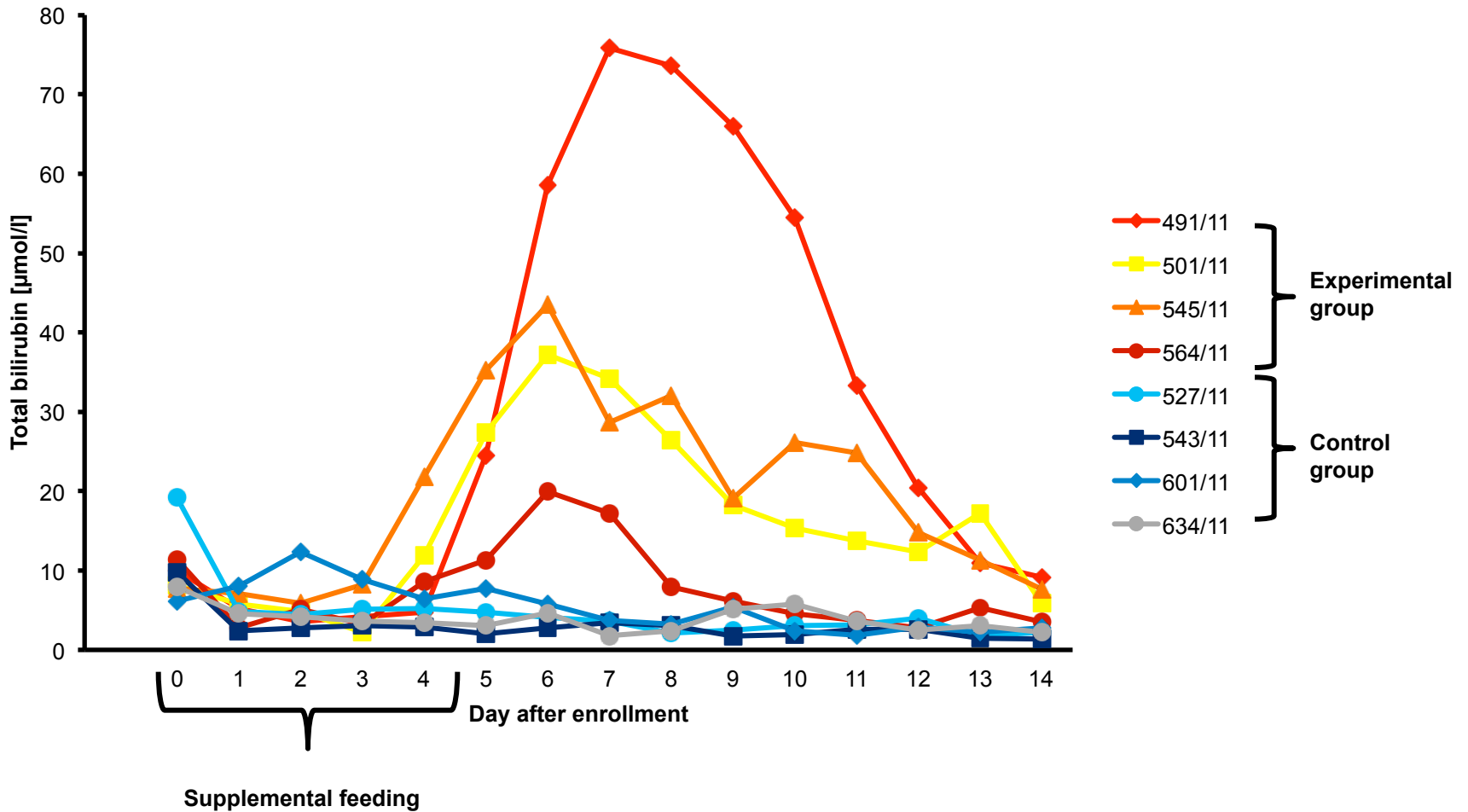
Experimental design :

- Feeding of the product according to the recommendations of the manufacturer
- Use of 2 batches from affected farms
- Duration of administration: 5 days
- Daily clinical examination for 15 days
- Daily examination of blood samples for 15 days

Feeding trial - results

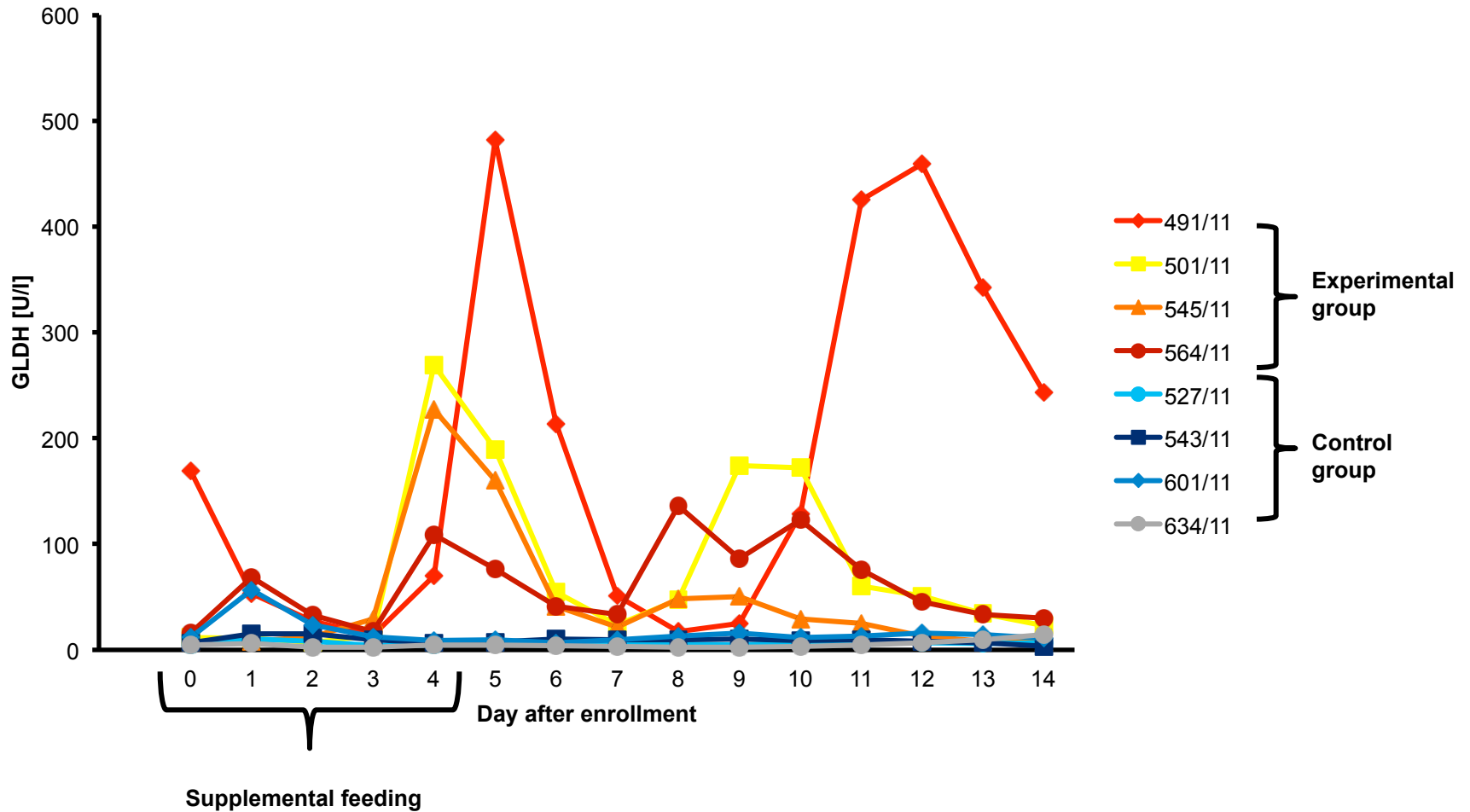
- None of the four calves of the experimental group showed signs of a disease
- 3 out of 4 calves of the experimental group drank less for one or two meals (day 4 or 5)

Feeding trial – results total bilirubin



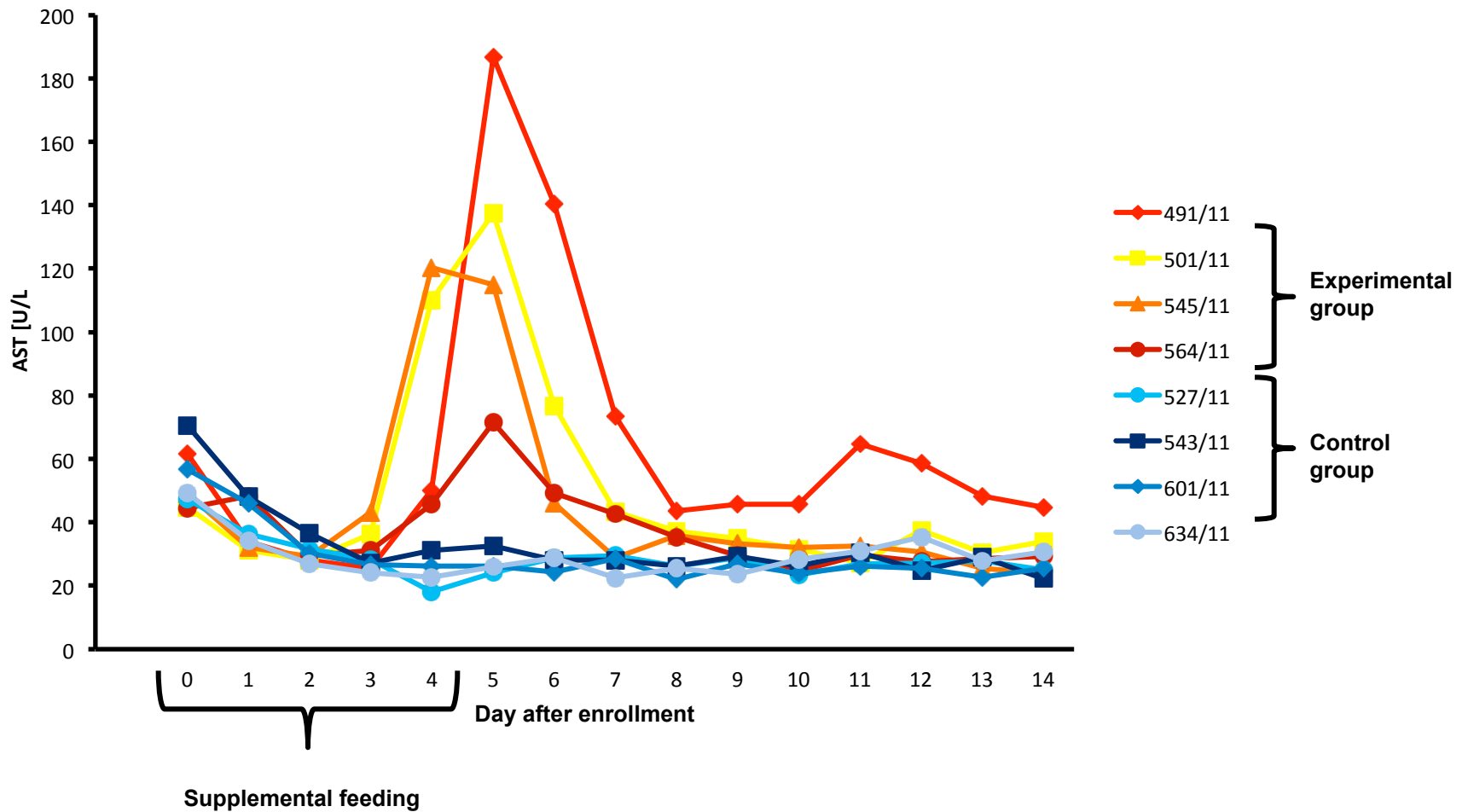
Feeding trial – results

GLDH



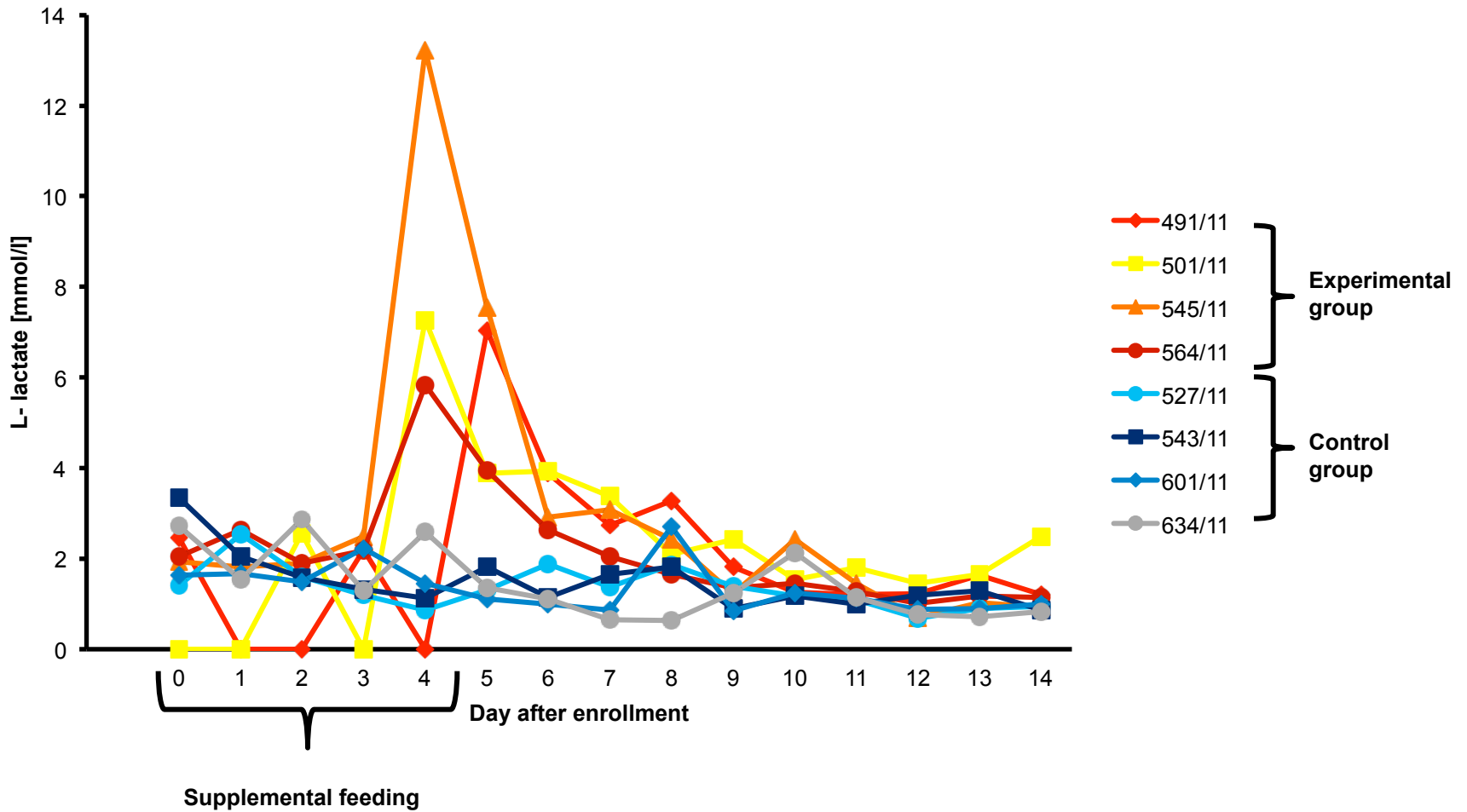
Feeding trial – results

AST



Feeding trial – results

L-lactate



Summary

- Unusual cumulation of liver disease in young calves
- Epidemiological evidence of a commercial supplement as causal agent
- Results of a feeding trial seem to confirm the suspicion (at least for two batches in trial)
- Toxicological principle remains obscure

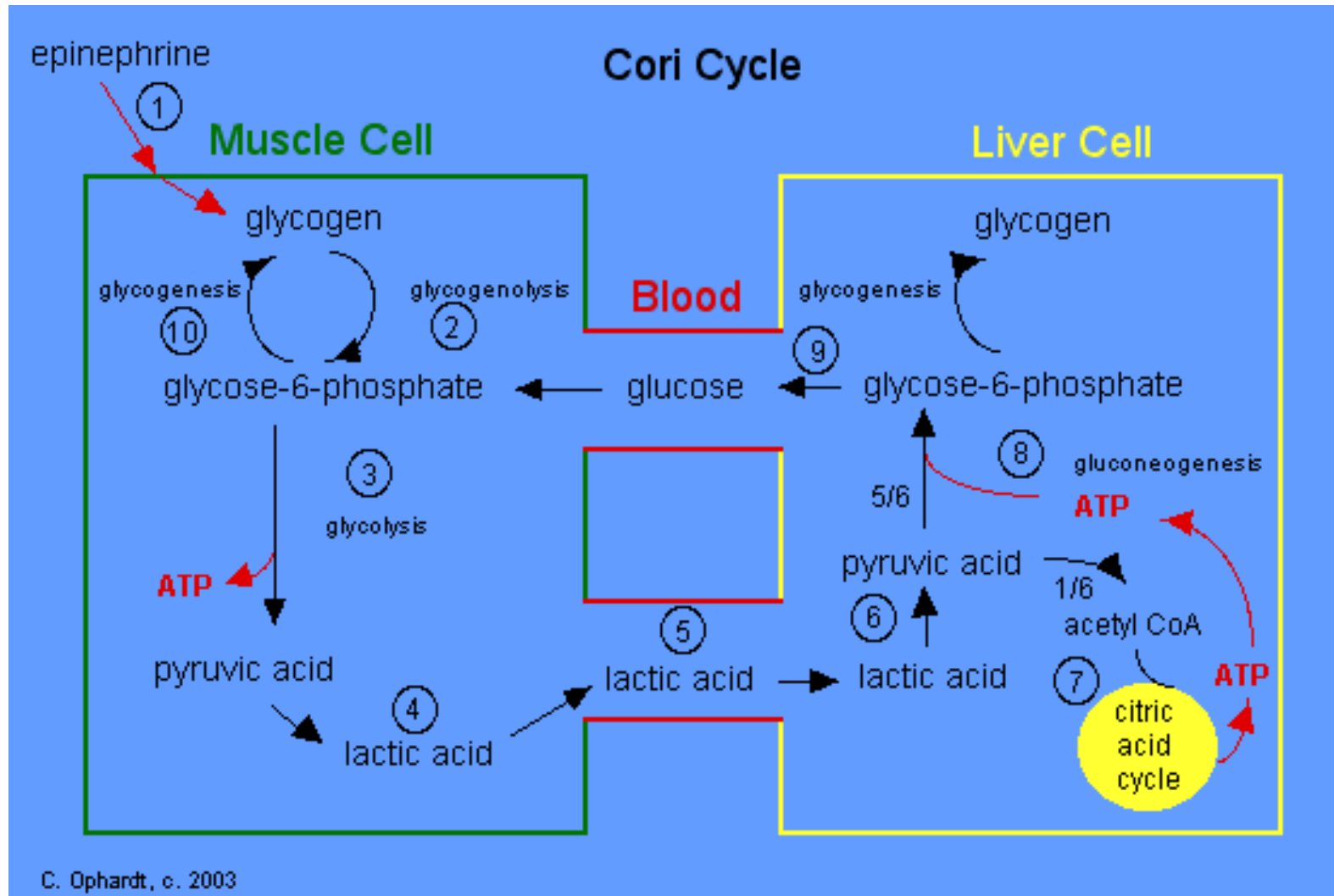
Thank you very much for your attention !



LMU München

Klinik für Wiederkäuer
mit Ambulanz und Bestandsbetreuung

Cori Cycle



Urea Cycle



Klinik für Wiederkäuer
mit Ambulanz und Bestandsbetreuung

